

# COVID-19 Image Data Collection

Joseph Paul Cohen<sup>1,2</sup> Paul Morrison<sup>3</sup> Lan Dao<sup>4</sup>

## Abstract

This paper describes the initial COVID-19 open image data collection. It was created by assembling medical images from websites and publications and currently contains 123 frontal view X-rays.

## 1. Motivation

In the context of a COVID-19 pandemic, is it crucial to streamline diagnosis. Data is the first step to developing any diagnostic tool or treatment. While there exist large public datasets of more typical chest X-rays (Wang et al., 2017; Bustos et al., 2019; Irvin et al., 2019; Johnson et al., 2019; Demner-Fushman et al., 2016), there is no collection of COVID-19 chest X-rays or CT scans designed to be used for computational analysis.

In this paper, we describe the public database of pneumonia cases with chest X-ray or CT images, specifically COVID-19 cases as well as MERS, SARS, and ARDS. Data will be collected from public sources in order not to infringe patient confidentiality. Example images shown in Figure 1.

Our team believes that this database can dramatically improve identification of COVID-19. Notably, this would provide essential data to train and test a Deep Learning-based system, likely using some form of transfer learning. These tools could be developed to identify COVID-19 characteristics as compared to other types of pneumonia or in order to predict survival.

Currently, all images and data are released under the following URL: <https://github.com/ieee8023/covid-chestxray-dataset>. As stated above, images collected have already been made public.

## 2. Expected outcome

This dataset can be used to study the progress of COVID-19 and how its radiological findings vary from other types of

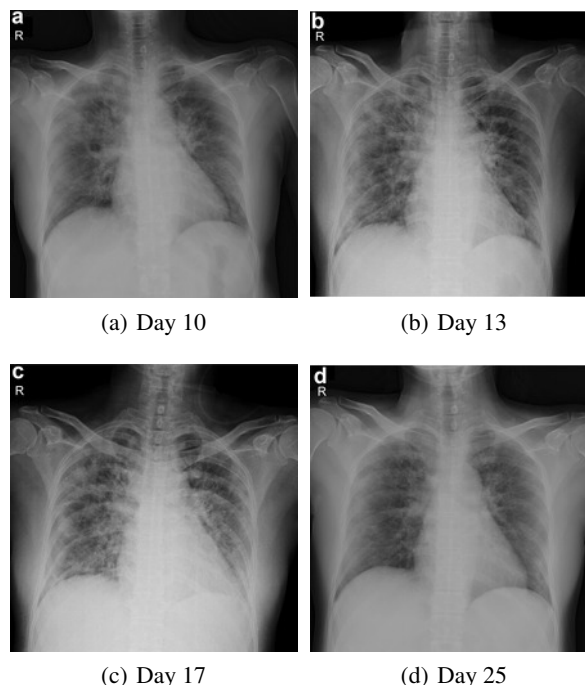


Figure 1. Example images from the same patient (#19) extracted from Cheng et al. (2020). This 55 year old female survived a COVID-19 infection.

pneumonia. Similarly to the outcome of the Chest Xray14 (Wang et al., 2017) dataset which enabled significant advances in medical imaging, tools can be developed to predict not only the type of pneumonia, but also its outcome. Eventually, our model could take inspiration from work by Rajpurkar et al. (2017), which could predict pneumonia, as well as Cohen et al. (2019), which deployed such models.

Tools could be built to triage cases in the absence of physical tests, particularly in the context of polymerase chain reaction (PCR) tests shortage (Satyanarayana, 2020; Kelly Geraldine Malone, 2020). These tools could predict patient outcomes such as survival, allowing a physician to plan ahead for specific patients and facilitate management. In extreme situations, where physicians could be faced with the extraordinary decision to choose which patient should be allocated healthcare resources (Yascha Mounk, 2020), such a tool could potentially serve as a measuring device.

<sup>1</sup>Mila, Quebec Artificial Intelligence Institute <sup>2</sup>University of Montreal <sup>3</sup>Department of Mathematics and Computer Science, Fontbonne University <sup>4</sup>Faculty of Medicine, University of Montreal. Correspondence to: Joseph Paul Cohen <joseph@josephpcohen.com>.

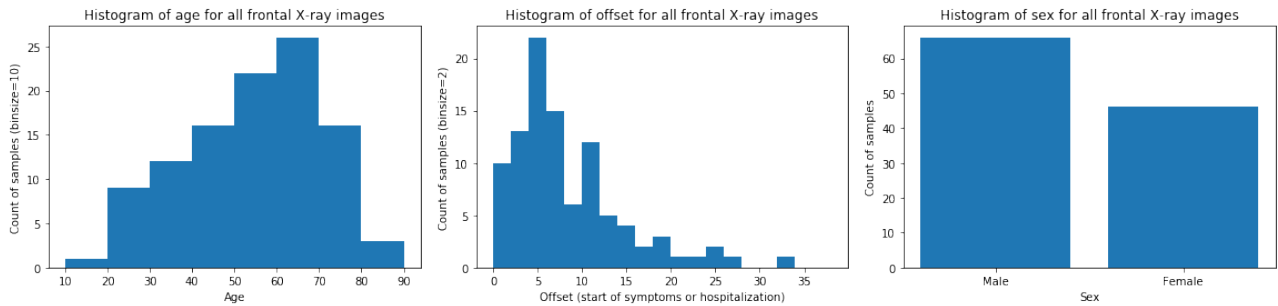


Figure 2. Demographics for each frontal X-ray image

Type of pneumonia	PA	AP	AP Supine
SARSr-CoV-2 or COVID-19	76	11	13
SARSr-CoV-1 or SARS	11	0	0
<i>Streptococcus spp.</i>	6	0	0
<i>Pneumocystis spp.</i>	1	0	0
ARDS	4	0	0

Table 1. Counts of each finding and view. PA = posteroanterior, AP = anteroposterior, AP Supine = laying down, SARSr-CoV-2 = Severe acute respiratory syndrome-related coronavirus 2, SARS-CoV-1 or SARS = Severe acute respiratory syndrome-related coronavirus 1, ARDS = acute respiratory distress syndrome

Furthermore, these tools could monitor the progression of COVID-19 positive patients in order to better track the evolution of their condition. Ultimately, this dataset and its analysis could help us better understand the dynamics of the disease and better prepare treatments.

### 3. Dataset

The current statistics as of March 25th 2020 are shown in Table 1. For each image, attributes shown in Table 2 are collected. Data is largely compiled from websites such as Radiopaedia.org, the Italian Society of Medical and Interventional Radiology<sup>1</sup>, and Figure1.com<sup>2</sup>. Images are extracted from online publications, website, or directly from the PDF using the tool pdfimages<sup>3</sup>. The goal during this process is to maintain the quality of the images.

Data was collected from the following papers: (Phan et al., 2020; Liu et al., 2020; Chen et al., 2020; Paul et al., 2004; Silverstein et al., 2020; Shi et al., 2020; Holshue et al., 2020; Ng et al., 2020; Kong & Agarwal, 2020; Lim et al., 2020; Zu et al., 2020; Cheng et al., 2020; jin Zhang et al., 2020; Lee et al., 2020; Wu et al., 2020; Yoon et al., 2020; Hsieh et al., 2020; Cuong et al., 2020; Thevarajan et al., 2020; Wei et al., 2020)

<sup>1</sup><https://www.sirm.org/category/senza-categoria/covid-19/>

<sup>2</sup><https://www.figure1.com/covid-19-clinical-cases>

<sup>3</sup><https://poppler.freedesktop.org/>

Attribute	Description
Patient ID	Internal identifier
Offset	Number of days since the start of symptoms or hospitalization for each image. If a report indicates "after a few days", then 5 days is assumed.
Sex	Male (M), Female (F), or blank
Age	Age of the patient in years
Finding	Type of pneumonia
Survival	Yes (Y) or no (N)
View	Posteroanterior (PA), Anteroposterior (AP), AP Supine (APS), or Lateral (L) for X-rays; Axial or Coronal for CT scans
Modality	CT, X-ray, or something else
Date	Date on which the image was acquired
Location	Hospital name, city, state, country
Filename	Name with extension
doi	Digital object identifier (DOI) of the research article
url	URL of the paper or website where the image came from
License	License of the image such as CC BY-NC-SA. Blank if unknown
Clinical notes	Clinical notes about the image and/or the patient
Other notes	e.g. credit

Table 2. Descriptions of each attribute of the metadata

### References

Bustos, Aurelia, Pertusa, Antonio, Salinas, Jose-Maria, and de la Iglesia-Vayá, Maria. PadChest: A large chest x-ray image dataset with multi-label annotated reports. *arXiv preprint*, 1 2019.

Chen, Nanshan, Zhou, Min, Dong, Xuan, Qu, Jieming, Gong, Fengyun, Han, Yang, Qiu, Yang, Wang, Jingli, Liu, Ying, Wei, Yuan, Xia, Jia'an, Yu, Ting, Zhang, Xinxin,

- and Zhang, Li. Epidemiological and clinical characteristics of 99 cases of 2019 novel coronavirus pneumonia in wuhan, china: a descriptive study. *The Lancet*, February 2020. doi: 10.1016/s0140-6736(20)30211-7.
- Cheng, Shao-Chung, Chang, Yuan-Chia, Chiang, Yu-Long Fan, Chien, Yu-Chan, Cheng, Mingte, Yang, Chin-Hua, Huang, Chia-Husn, and Hsu, Yuan-Nian. First case of coronavirus disease 2019 (COVID-19) pneumonia in taiwan. *Journal of the Formosan Medical Association*, March 2020. doi: 10.1016/j.jfma.2020.02.007.
- Cohen, Joseph Paul, Bertin, Paul, and Frappier, Vincent. Chester: A Web Delivered Locally Computed Chest X-Ray Disease Prediction System. *arXiv:1901.11210*, 2019.
- Cuong, Le Van, Giang, Hoang Thi Nam, Linh, Le Khac, Shah, Jaffer, Sy, Le Van, Hung, Trinh Huu, Reda, Abdullah, Truong, Luong Ngoc, Tien, Do Xuan, and Huy, Nguyen Tien. The first vietnamese case of COVID-19 acquired from china. *The Lancet Infectious Diseases*, February 2020. doi: 10.1016/s1473-3099(20)30111-0.
- Demner-Fushman, Dina, Kohli, Marc D., Rosenman, Marc B., Shooshan, Sonya E., Rodriguez, Laritza, Antani, Sameer, Thoma, George R., and McDonald, Clement J. Preparing a collection of radiology examinations for distribution and retrieval. *Journal of the American Medical Informatics Association*, 3 2016. doi: 10.1093/jamia/ocv080.
- Holshue, Michelle L., DeBolt, Chas, Lindquist, Scott, Lofy, Kathy H., Wiesman, John, Bruce, Hollianne, Spitters, Christopher, Ericson, Keith, Wilkerson, Sara, Tural, Ahmet, Diaz, George, Cohn, Amanda, Fox, LeAnne, Patel, Anita, Gerber, Susan I., Kim, Lindsay, Tong, Suxiang, Lu, Xiaoyan, Lindstrom, Steve, Pallansch, Mark A., Weldon, William C., Biggs, Holly M., Uyeki, Timothy M., and Pillai, Satish K. First case of 2019 novel coronavirus in the united states. *New England Journal of Medicine*, March 2020. doi: 10.1056/nejmoa2001191.
- Hsih, Wen-Hsin, Cheng, Meng-Yu, Ho, Mao-Wang, Chou, Chia-Huei, Lin, Po-Chang, Chi, Chih-Yu, Liao, Wei-Chih, Chen, Chih-Yu, Leong, Lih-Ying, Tien, Ni, Lai, Huan-Cheng, Lai, Yi-Chyi, and Lu, Min-Chi. Featuring COVID-19 cases via screening symptomatic patients with epidemiologic link during flu season in a medical center of central taiwan. *Journal of Microbiology, Immunology and Infection*, March 2020. doi: 10.1016/j.jmii.2020.03.008.
- Irvin, Jeremy, Rajpurkar, Pranav, Ko, Michael, Yu, Yifan, Ciurea-Ilcus, Silviana, Chute, Chris, Marklund, Henrik, Haghighi, Behzad, Ball, Robyn, Shpanskaya, Katie, Seekins, Jayne, Mong, David A., Halabi, Safwan S., Sandberg, Jesse K., Jones, Ricky, Larson, David B., Langlotz, Curtis P., Patel, Bhavik N., Lungren, Matthew P., and Ng, Andrew Y. CheXpert: A Large Chest Radiograph Dataset with Uncertainty Labels and Expert Comparison. In *AAAI Conference on Artificial Intelligence*, 1 2019.
- jin Zhang, Jin, Dong, Xiang, yuan Cao, Yi, dong Yuan, Ya, bin Yang, Yi, qin Yan, You, Akdis, Cezmi A., and dong Gao, Ya. Clinical characteristics of 140 patients infected with SARS-CoV-2 in wuhan, china. *Allergy*, February 2020. doi: 10.1111/all.14238.
- Johnson, Alistair E. W., Pollard, Tom J., Berkowitz, Seth J., Greenbaum, Nathaniel R., Lungren, Matthew P., Deng, Chih-ying, Mark, Roger G., and Horng, Steven. MIMIC-CXR: A large publicly available database of labeled chest radiographs. *Nature Scientific Data*, 1 2019. doi: 10.1038/s41597-019-0322-0.
- Kelly Geraldine Malone. Testing backlog linked to shortage of chemicals needed for COVID-19 test — CTV News, 3 2020.
- Kong, Weifang and Agarwal, Prachi P. Chest imaging appearance of COVID-19 infection. *Radiology: Cardiothoracic Imaging*, January 2020. doi: 10.1148/ryct.2020200028.
- Lee, Nan-Yao, Li, Chia-Wen, Tsai, Huey-Pin, Chen, Po-Lin, Syue, Ling-Shan, Li, Ming-Chi, Tsai, Chin-Shiang, Lo, Ching-Lung, Hsueh, Po-Ren, and Ko, Wen-Chien. A case of COVID-19 and pneumonia returning from macau in taiwan: Clinical course and anti-SARS-CoV-2 IgG dynamic. *Journal of Microbiology, Immunology and Infection*, March 2020. doi: 10.1016/j.jmii.2020.03.003.
- Lim, Jaegyun, Jeon, Seunghyun, Shin, Hyun-Young, Kim, Moon Jung, Seong, Yu Min, Lee, Wang Jun, Choe, Kang-Won, Kang, Yu Min, Lee, Baekseung, and Park, Sang-Joon. Case of the index patient who caused tertiary transmission of coronavirus disease 2019 in korea: the application of lopinavir/ritonavir for the treatment of COVID-19 pneumonia monitored by quantitative RT-PCR. *Journal of Korean Medical Science*, 2020. doi: 10.3346/jkms.2020.35.e79.
- Liu, Ying-Chu, Liao, Ching-Hui, Chang, Chin-Fu, Chou, Chu-Chung, and Lin, Yan-Ren. A locally transmitted case of SARS-CoV-2 infection in taiwan. *New England Journal of Medicine*, March 2020. doi: 10.1056/nejmc2001573.
- Ng, Ming-Yen, Lee, Elaine YP, Yang, Jin, Yang, Fangfang, Li, Xia, Wang, Hongxia, sze Lui, Macy Mei, Lo, Christine Shing-Yen, Leung, Barry, Khong, Pek-Lan, Hui, Christopher Kim-Ming, yung Yuen, Kwok, and Kuo,

- Michael David. Imaging profile of the COVID-19 infection: Radiologic findings and literature review. *Radiology: Cardiothoracic Imaging*, February 2020. doi: 10.1148/ryct.2020200034.
- Paul, Narinder S., Roberts, Heidi, Butany, Jagdish, Chung, TaeBong, Gold, Wayne, Mehta, Sangeeta, Konen, Eli, Rao, Anuradha, Provost, Yves, Hong, Harry H., Zelovitsky, Leon, and Weisbrod, Gordon L. Radiologic pattern of disease in patients with severe acute respiratory syndrome: The toronto experience. *RadioGraphics*, March 2004. doi: 10.1148/rg.242035193.
- Phan, Lan T., Nguyen, Thuong V., Luong, Quang C., Nguyen, Thinh V., Nguyen, Hieu T., Le, Hung Q., Nguyen, Thuc T., Cao, Thang M., and Pham, Quang D. Importation and human-to-human transmission of a novel coronavirus in vietnam. *New England Journal of Medicine*, February 2020. doi: 10.1056/nejmc2001272.
- Rajpurkar, Pranav, Hannun, Awni Y., Haghpanshi, Masoumeh, Bourn, Codie, and Ng, Andrew Y. Cardiologist-Level Arrhythmia Detection with Convolutional Neural Networks, 7 2017.
- Satyanarayana, Megha. Shortage of RNA extraction kits hampers efforts to ramp up COVID-19 coronavirus testing, 3 2020.
- Shi, Heshui, Han, Xiaoyu, and Zheng, Chuansheng. Evolution of CT manifestations in a patient recovered from 2019 novel coronavirus (2019-nCoV) pneumonia in wuhan, china. *Radiology*, April 2020. doi: 10.1148/radiol.2020200269.
- Silverstein, William Kyle, Stroud, Lynfa, Cleghorn, Graham Edward, and Leis, Jerome Allen. First imported case of 2019 novel coronavirus in canada, presenting as mild pneumonia. *The Lancet*, February 2020. doi: 10.1016/s0140-6736(20)30370-6.
- Thevarajan, Irani, Nguyen, Thi H. O., Koutsakos, Marios, Druce, Julian, Caly, Leon, van de Sandt, Carolien E., Jia, Xiaoxiao, Nicholson, Suellen, Catton, Mike, Cowie, Benjamin, Tong, Steven Y. C., Lewin, Sharon R., and Kedzierska, Katherine. Breadth of concomitant immune responses prior to patient recovery: a case report of non-severe COVID-19. *Nature Medicine*, March 2020. doi: 10.1038/s41591-020-0819-2.
- Wang, Xiaosong, Peng, Yifan, Lu, Le, Lu, Zhiyong, Bagheri, Mohammadhadi, and Summers, Ronald M. ChestX-ray8: Hospital-scale Chest X-ray Database and Benchmarks on Weakly-Supervised Classification and Localization of Common Thorax Diseases. In *Computer Vision and Pattern Recognition*, 2017. doi: 10.1109/CVPR.2017.369.
- Wei, Jiangping, Xu, Huaxiang, Xiong, Jingliang, Shen, Qinglin, Fan, Bing, Ye, Chenglong, Dong, Wentao, and Hu, Fangfang. 2019 novel coronavirus (COVID-19) pneumonia: Serial computed tomography findings. *Korean Journal of Radiology*, 2020. doi: 10.3348/kjr.2020.0112.
- Wu, Jian, Liu, Jun, Zhao, Xinguo, Liu, Chengyuan, Wang, Wei, Wang, Dawei, Xu, Wei, Zhang, Chunyu, Yu, Jiong, Jiang, Bin, Cao, Hongcui, and Li, Lanjuan. Clinical characteristics of imported cases of COVID-19 in jiangsu province: A multicenter descriptive study. *Clinical Infectious Diseases*, February 2020. doi: 10.1093/cid/ciaa199.
- Yascha Mounk. Coronavirus: Extraordinary Decisions For Italian Doctors - The Atlantic, 3 2020.
- Yoon, Soon Ho, Lee, Kyung Hee, Kim, Jin Yong, Lee, Young Kyung, Ko, Hongseok, Kim, Ki Hwan, Park, Chang Min, and Kim, Yun-Hyeon. Chest radiographic and CT findings of the 2019 novel coronavirus disease (COVID-19): Analysis of nine patients treated in korea. *Korean Journal of Radiology*, 2020. doi: 10.3348/kjr.2020.0132.
- Zu, Zi Yue, Jiang, Meng Di, Xu, Peng Peng, Chen, Wen, Ni, Qian Qian, Lu, Guang Ming, and Zhang, Long Jiang. Coronavirus disease 2019 (COVID-19): A perspective from china. *Radiology*, February 2020. doi: 10.1148/radiol.2020200490.